



## SUSPECTED ASSOCIATION OF AN ALLERGIC REACTION WITH TITANIUM DENTAL IMPLANTS: A CLINICAL REPORT

**Hiroshi Egusa, DDS, PhD,<sup>a</sup> Nagakazu Ko, DDS, PhD,<sup>b</sup>  
Tsunetoshi Shimazu, MD,<sup>c</sup> and Hirofumi Yatani, DDS, PhD<sup>d</sup>**  
Osaka University Graduate School of Dentistry, Osaka, Japan

Recent reports have questioned whether metal sensitivity may occur after exposure to titanium. This clinical report demonstrates the emergence of facial eczema in association with a titanium dental implant placed for a mandibular overdenture supported by 2 implants. Complete remission was achieved by the removal of the titanium material. This clinical report raises the possibility that in rare circumstances, for some patients, the use of titanium dental implants may induce an allergic reaction. (*J Prosthet Dent* 2008;100:344-347)

Recently, metal allergies from dental restorations, including allergies to nickel, iron, cobalt, and zinc, have been reported in association with oral lichen planus,<sup>1-3</sup> hand eczema, or palmoplantar pustulosis.<sup>4-6</sup> In contrast, titanium is considered to be a biocompatible material.<sup>7</sup> However, in light of recent clinical reports regarding contact dermatitis or granulomatous reactions to titanium upon its use in pacemakers,<sup>8-11</sup> hip prostheses,<sup>12-15</sup> surgical clips,<sup>16</sup> or osteosynthesis,<sup>17</sup> there is debate with regard to titanium allergies. In addition, titanium has also been reported to possibly cause generalized health problems,<sup>18</sup> and the potential for adverse human tissue responses to titanium dioxide, which always covers the surface of titanium materials, has been reported.<sup>19</sup> Nawaz and Wall recently reported on a patient demonstrating a drug rash with eosinophilia and systemic symptoms (DRESS) syndrome, which reflects a serious hypersensitivity reaction to drugs, in association with titanium bioprosthetic implants.<sup>20</sup>

Sensitivity to titanium is characterized by the local presence of abundant macrophages and T lymphocytes and the absence of B lymphocytes, indicat-

ing Type 4 hypersensitivity.<sup>21,22</sup> Studies evaluating the oral tissue changes adjacent to titanium implants<sup>23</sup> or titanium plates<sup>24,25</sup> in patients reported no evidence of inflammatory response and no association between the identification of pigmented debris in the tissues and clinical symptoms. However, the relationship between titanium dental implants and clinically relevant hypersensitivity has been recently suggested.<sup>26,27</sup> These reports raise the question that metal sensitivity may arise after exposure to titanium for some patients in certain circumstances. This clinical report demonstrates the emergence of eczema localized to the perioperative facial area after receiving titanium dental implants, in which a complete remission was subsequently achieved by the removal of the titanium material.

### CLINICAL REPORT

In May 1998, a 50-year-old Japanese woman was referred to the Ko Dental Clinic, Osaka, Japan, with a 2-year history of inflammatory skin lesions on her face. A physical examination revealed persistent skin rashes characterized by extremely red and

itchy patches disseminated over her face; clinically, the signs were typical of eczema (Fig. 1). Laboratory data and complete blood counts were within normal limits. She had neither systemic diseases nor previous contact or atopic eczema, nor hypersensitivity reactions to metals. She was edentulous and wore a complete maxillary denture and a mandibular overdenture supported by 2 implants (Fig. 2). A detailed medical and dental history revealed that, 2 years earlier, the patient had received 2 dental implants in her mandible (Osseotite Implant System; Biomet 3i, Palm Beach Gardens, Fla). One week after implant placement, rashes appeared on her mandibulofacial skin, and they gradually disseminated over her entire face. Although laboratory tests of urine and blood were normal and the patient exhibited no other symptoms, the eczema persisted.

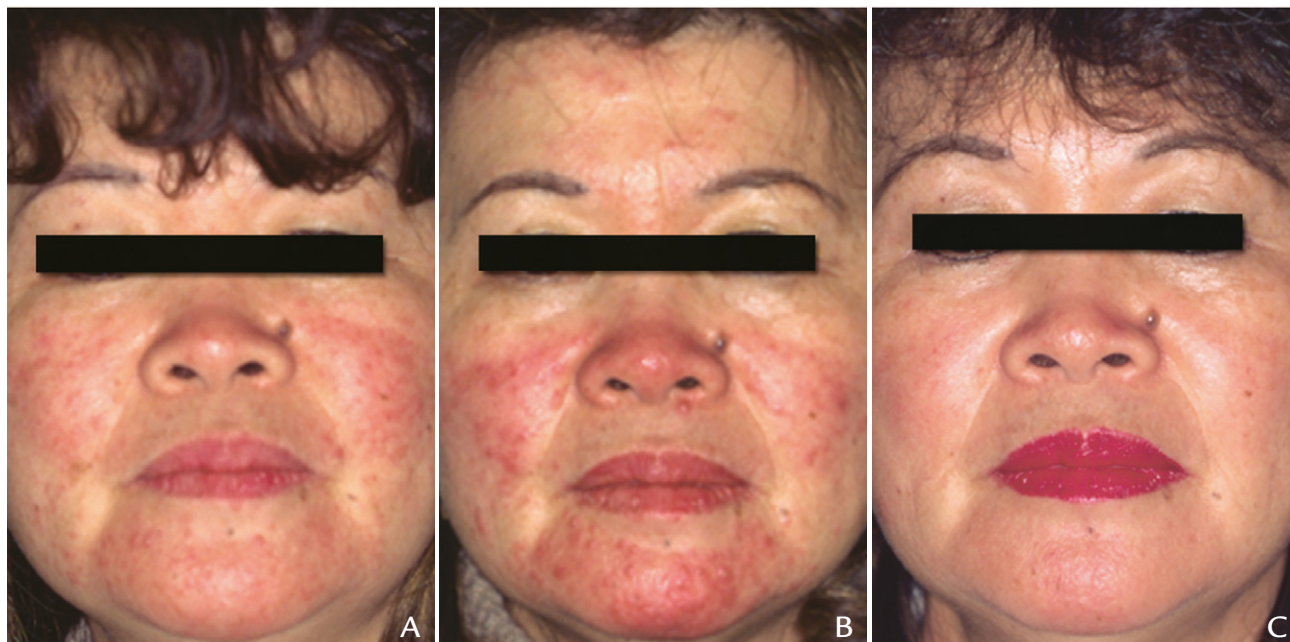
Chronic low-level metal exposure may occasionally result in metal sensitization and undesirable side effects.<sup>28</sup> Since the dental implants, which were purported by the manufacturer to be made of ASTM grade I high-purity titanium (99.64%), were the only extraneous substance chronically in

<sup>a</sup>Assistant Professor, Department of Fixed Prosthodontics.

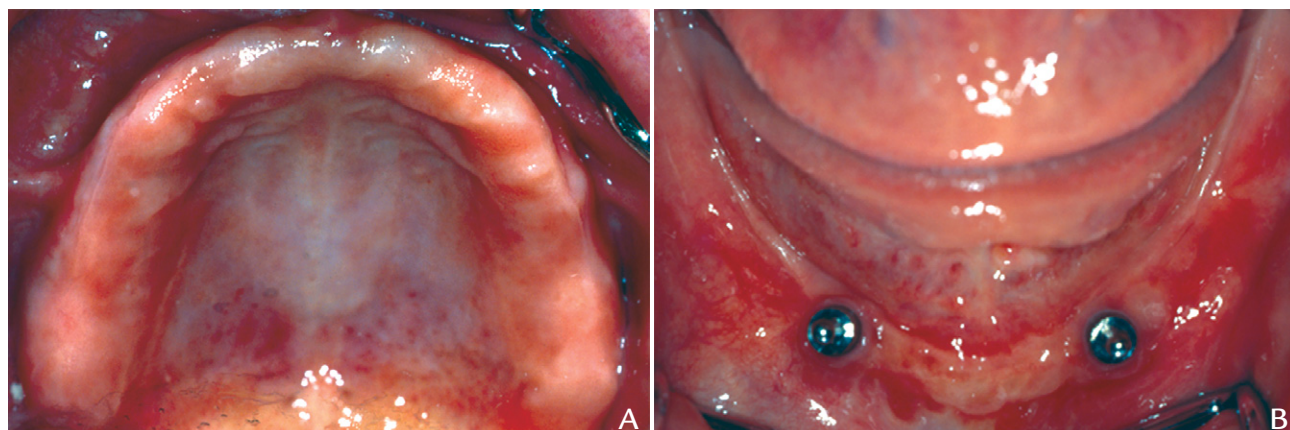
<sup>b</sup>Private practice, Osaka, Japan.

<sup>c</sup>Private practice, Kyoto, Japan.

<sup>d</sup>Professor and Chair, Department of Fixed Prosthodontics.



**1** A, Facial eczema lasted for 2 years after receiving titanium dental implants. B, One week after removal of dental implants, symptoms of eczema temporarily worsened. C, Ten months after removal of dental implants.

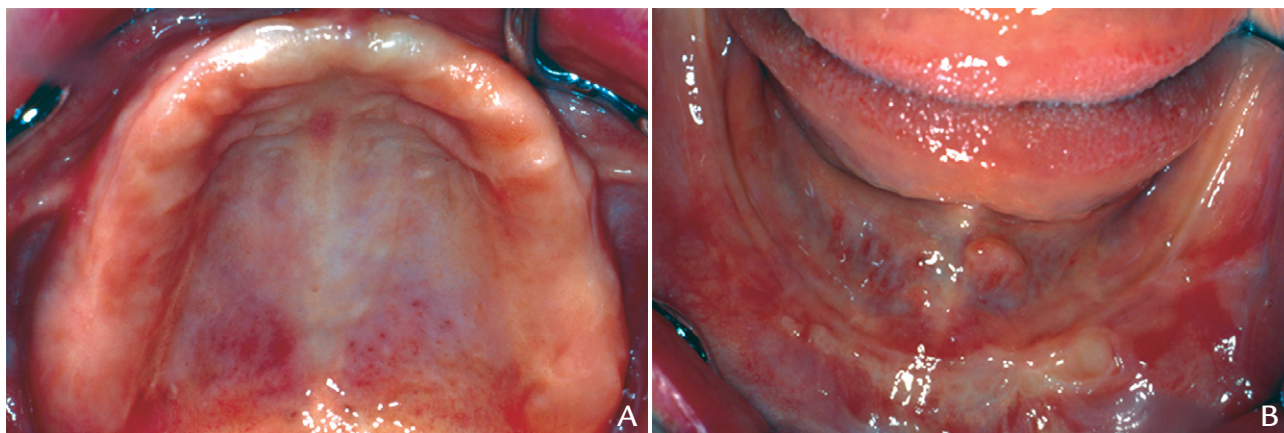


**2** Oral photographs of patient before removal of dental implants. A, Edentulous maxillary arch. B, Edentulous mandibular arch with 2 dental implants.

contact with her body tissues, a possible relationship between the eczema and a titanium allergy induced by the dental implants was suspected. Patients that are affected by metal allergens are generally diagnosed using the epicutaneous (patch) test. However, such testing may induce false-positive (irritative) reactions and may in itself sensitize or exacerbate symptoms; therefore, the patient did not desire to undergo the patch test. Alternatively, lymphocyte transformation tests (LTT), which have been recently validated for metal sensitivity testing, including testing for titanium hypersensitivity,<sup>18, 26, 29</sup> were used. The

LTT was performed as described in detail for detecting metal sensitivity.<sup>6, 18</sup> Briefly,  $0.2 \times 10^6$  peripheral blood mononuclear cells (PBMCs) in 200  $\mu$ l of Roswell Park Memorial Institute (RPMI) medium 1640 (Nacalai Tesque, Kyoto, Japan) containing 20% autologous plasma were pipetted into the wells of a 96-well cell culture plate (Corning, Inc, Lowell, Mass). Antigen solutions of 4%  $\text{TiCl}_3$ , 0.2%  $\text{HAuCl}_4$ , 0.1%  $\text{CH}_3\text{COOAg}$ , 0.2%  $\text{PdCl}_2$ , 0.4%  $\text{InCl}_3$ , 0.02%  $\text{HgCl}_2$ , and 1%  $\text{NiSO}_4$  (Nacalai Tesque) were prepared in 6 dilution series ( $1/5^n$ ) each, and 20  $\mu$ l of each antigen solution was added to the PBMCs in the culture well in trip-

licates. Following 72 hours of incubation at 37°C with 5%  $\text{CO}_2$ , cells were pulsed for 18 hours with 10.6 KBq methyl-<sup>3</sup>H-thymidine (Moravek Biochemicals, Inc, Brea, Calif) per well, and the radioactivity was measured in a liquid scintillation counter (Top-Count; PerkinElmer, Inc, Waltham, Mass). The counts per minute (cpm) were converted to a stimulation index (SI) representing the cpm in the test well divided by the average cpm in negative control wells. Conventionally, a cutoff of  $\text{SI} \geq 1.8$  in at least 1 concentration of the 6 dilution series defined a positive reaction for the metals tested.<sup>6</sup> LTT revealed a specific



**3** Oral photographs of patient 10 months after removal of dental implants. A, Edentulous maxillary arch. B, Edentulous mandibular arch.

reaction to  $\text{TiCl}_3$ ,  $\text{NiSO}_4$ , and  $\text{HgCl}_2$  with  $\text{SI}_{\text{max}}$  of 2.39, 2.92, and 32.89, respectively; all other tests were within the normal range (normal  $<1.8$  for all materials tested).

Based on the clinical history and the positive LTT index for titanium, the patient's eczema was concluded to be induced by a titanium allergy. Therefore, all of the implants were surgically removed in July 1998 with the patient's consent. One week later, the symptoms of eczema temporarily worsened (Fig. 1, B). However, the symptoms thereafter gradually improved, without requiring the prescription of any oral or topical medications, and complete resolution was achieved within 10 months (Fig. 1, C, and Fig. 3). The patient did not desire to undergo any further implant placement. Although the retention and stability of the mandibular denture were reduced without implants for support, the denture has since been managed by denture relining, and it has functioned acceptably to date. When the patient was last seen in April 2008, she was doing well and had no signs of recurrence.

## DISCUSSION

Within the last 20 years, outcomes of treatment with dental implants have become increasingly predictable. Due to its recognized biocompatibility, titanium is not considered to provoke allergic reactions, although any

foreign material has a potential to trigger an allergic response in certain circumstances.

This clinical report demonstrates the emergence of eczema in association with titanium dental implants. A complete remission was achieved by the removal of the titanium material without oral or topical medications being prescribed. Due to both ethical and practical reasons, a reexposure of the patient to the suspected titanium allergen was not performed. However, it is noted that the symptoms of eczema temporarily worsened after the removal of the implants. This sudden turn for the worse in the patient's condition suggests that the patient was rechallenged with titanium debris as an allergen during the titanium removal surgery. The patient did not have a history of dermatitis due to metal devices. At this time, there is no evidence that there is an increased risk of a reaction to an implanted device in patients who have skin patch or LTT sensitivity but no history of reaction to metallic materials. The importance of this line of investigation is increasing.<sup>30</sup>

Patients with a suspected titanium allergy from dental implants have been extremely rare, and this phenomenon has not yet been widely recognized in dental and medical fields. The history of titanium dental implant treatment is only a few decades old. Before such dental implant treatment became widespread, few people were exposed

to titanium materials. This report suggests that dentists and physicians should be aware that the possibility of a titanium allergy from a dental implant in some patients cannot be entirely eliminated.

## SUMMARY

This clinical report presents a suspected association of an allergic reaction with titanium dental implants. It appears that in rare circumstances, for some patients, the titanium used in dental implants may induce an allergic reaction. The rare occurrence of such a response to titanium materials in clinical dentistry should, therefore, be further discussed and investigated.

## REFERENCES

1. Mobacken H, Hersle K, Sloberg K, Thilander H. Oral lichen planus: hypersensitivity to dental restoration material. *Contact Dermatitis* 1984;10:11-5.
2. Kato Y, Hayakawa R, Shiraki R, Ozeki K. A case of lichen planus caused by mercury allergy. *Br J Dermatol* 2003;148:1268-9.
3. Bratel J, Hakeberg M, Jontell M. Effect of replacement of dental amalgam on oral lichenoid reactions. *J Dent* 1996;24:41-5.
4. Nakayama H, Imakado S, Kasahara N, Matsuo S. Allergen control. An indispensable treatment for allergic contact dermatitis. *Dermatol Clin* 1990;8:197-204.
5. Nakamura K, Imakado S, Takizawa M, Adachi M, Sugaya M, Wakugawa M. Exacerbation of pustulosis palmaris et plantaris after topical application of metals accompanied by elevated levels of leukotriene B4 in pustules. *J Am Acad Dermatol* 2000;42:1021-5.



6. Yanagi T, Shimizu T, Abe R, Shimizu H. Zinc dental fillings and palmoplantar pustulosis. *Lancet* 2005;366:1050.
7. Singh R, Dahotre NB. Corrosion degradation and prevention by surface modification of biometallic materials. *J Mater Sci Mater Med* 2007;18:725-51.
8. Abdallah HI, Balsara RK, O'Riordan AC. Pacemaker contact sensitivity: clinical recognition and management. *Ann Thorac Surg* 1994;57:1017-8.
9. Verbov J. Pacemaker contact sensitivity. *Contact Dermatitis* 1985;12:173.
10. Viraben R, Boulinguez S, Alba C. Granulomatous dermatitis after implantation of a titanium-containing pacemaker. *Contact Dermatitis* 1995;33:437.
11. Yamauchi R, Morita A, Tsuji T. Pacemaker dermatitis from titanium. *Contact Dermatitis* 2000;42:52-3.
12. Lalor PA, Gray AB, Wright S, Railton GT, Freeman MA, Revell PA. Contact sensitivity to titanium in a hip prosthesis? *Contact Dermatitis* 1990;23:193-4.
13. Lalor PA, Revell PA, Gray AB, Wright S, Railton GT, Freeman MA. Sensitivity to titanium. A cause of implant failure? *J Bone Joint Surg Br* 1991;73:25-8.
14. Witt JD, Swann M. Metal wear and tissue response in failed titanium alloy total hip replacements. *J Bone Joint Surg Br* 1991;73:559-63.
15. Granchi D, Cenni E, Trisolino G, Giunti A, Baldini N. Sensitivity to implant materials in patients undergoing total hip replacement. *J Biomed Mater Res B Appl Biomater* 2006;77:257-64.
16. Tamai K, Mitsumori M, Fujishiro S, Kokubo M, Ooya N, Nagata Y. A case of allergic reaction to surgical metal clips inserted for postoperative boost irradiation in a patient undergoing breast-conserving therapy. *Breast Cancer* 2001;8:90-2.
17. Thomas P, Bandl WD, Maier S, Summer B, Przybilla B. Hypersensitivity to titanium osteosynthesis with impaired fracture healing, eczema, and T-cell hyperresponsiveness in vitro: case report and review of the literature. *Contact Dermatitis* 2006;55:199-202.
18. Valentine-Thon E, Schiwara HW. Validity of MELISA for metal sensitivity testing. *Neuro Endocrinol Lett* 2003;24:57-64.
19. Moran CA, Mullick FG, Ishak KG, Johnson FB, Hummer WB. Identification of titanium in human tissues: Probable role in pathologic processes. *Hum Pathol* 1991;22:450-4.
20. Nawaz F, Wall BM. Drug rash with eosinophilia and systemic symptoms (DRESS) syndrome: suspected association with titanium bioprosthesis. *Am J Med Sci* 2007;334:215-8.
21. Holgers KM, Roupe G, Tjellström A, Bjursten LM. Clinical, immunological and bacteriological evaluation of adverse reactions to skin-penetrating titanium implants in the head and neck region. *Contact Dermatitis* 1992;27:1-7.
22. Hallab NJ, Mikecz K, Vermes C, Skipor A, Jacobs JJ. Orthopaedic implant related metal toxicity in terms of human lymphocyte reactivity to metal-protein complexes produced from cobalt-base and titanium-base implant alloy degradation. *Mol Cell Biochem* 2001;222:127-36.
23. Flatebø RS, Johannessen AC, Grønningsæter AG, Bøe OE, Gjerdet NR, Grung B, et al. Host response to titanium dental implant placement evaluated in a human oral model. *J Periodontol* 2006;77:1201-10.
24. Torgersen S, Gjerdet NR, Erichsen ES, Bang G. Metal particles and tissue changes adjacent to miniplates. A retrieval study. *Acta Odontol Scand* 1995;53:65-71.
25. Langford RJ, Frame JW. Tissue changes adjacent to titanium plates in patients. *J Craniomaxillofac Surg* 2002;30:103-7.
26. Müller KE, Valentine-Thon E. Hypersensitivity to titanium: clinical and laboratory evidence. *Neuro Endocrinol Lett* 2006; 27 Suppl 1:31-5.
27. du Preez LA, Butow KW, Swart TJ. Implant failure due to titanium hypersensitivity/allergy?--Report of a case. *SADJ* 2007;62:22, 24-5.
28. Geurtsen W. Biocompatibility of dental casting alloys. *Crit Rev Oral Biol Med* 2002;13:71-84.
29. Valentine-Thon E, Müller K, Guzzi G, Kreisel S, Ohnsorge P, Sandkamp M. LTT-MELISA is clinically relevant for detecting and monitoring metal sensitivity. *Neuro Endocrinol Lett* 2006;27 Suppl 1:17-24.
30. High WA, Ayers RA, Adams JR, Chang A, Fitzpatrick JE. Granulomatous reaction to titanium alloy: an unusual reaction to ear piercing. *J Am Acad Dermatol* 2006;55:716-20.

#### Corresponding author:

Dr Hiroshi Egusa  
 Department of Fixed Prosthodontics  
 Division of Oromaxillofacial Regeneration  
 Osaka University Graduate School of Dentistry  
 1-8 Yamadaoka, Suita-city  
 Osaka 565-0871  
 JAPAN  
 Fax: +81-6-6879-2947  
 E-mail: egu@dent.osaka-u.ac.jp

#### Acknowledgements

The authors thank Dr Rieko Ko and Dr Tamaki Nakano for their support.

Copyright © 2008 by the Editorial Council for  
*The Journal of Prosthetic Dentistry.*

## Availability of Journal Back Issues

As a service to our subscribers, copies of back issues of *The Journal of Prosthetic Dentistry* for the preceding 5 years are maintained and are available for purchase from Elsevier Inc until inventory is depleted. Please write to Elsevier Inc, Subscription Customer Service, 6277 Sea Harbor Dr, Orlando, FL 32887, or call 800-654-2452 or 407-345-4000 for information on availability of particular issues and prices.